

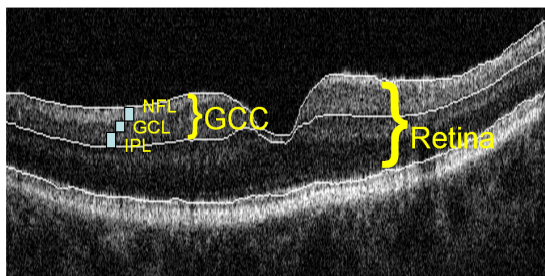
# Direct Ganglion Cell Assessment with the RTVue:

## The Ganglion Cell Complex Analysis

Mike Sinai, Ph.D.

Glaucoma is a multi-factorial optic neuropathy characterized by a loss of retinal ganglion cells with resulting visual impairment. The macula region contains over 50% of all retinal ganglion cells and is likely an ideal region to detect early cell loss and changes over time because of the high density of cells. Retinal ganglion cells encompass three layers in the retina, 1) the retinal nerve fiber layer (NFL) is made up of the ganglion cell axons, 2) the ganglion cell layer (GCL) is made up of the ganglion cell bodies, and 3) the inner-plexiform layer (IPL) is made up of the ganglion cell dendrites. All three layers, collectively known as the ganglion cell complex (GCC), become thinner as the ganglion cells die from glaucoma. The RTVue directly measures the thickness of these 3 layers and provides a unique analysis of the percent loss of these layers compared to an extensive normative database. The results are presented as significant loss from normal which makes clinical interpretation straightforward.

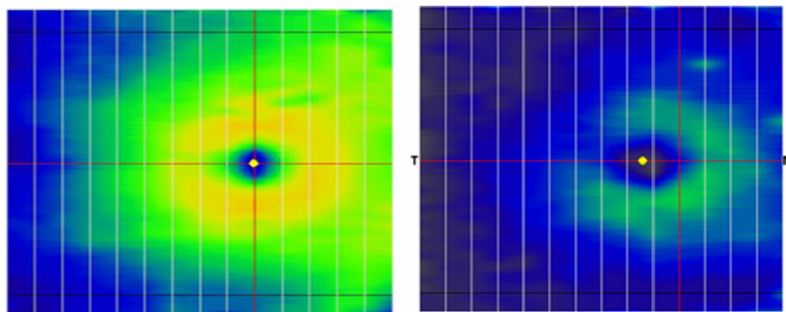
Figure 1 shows a cross sectional B-scan from the RTVue in the macula region. Because of the high depth resolution available in the technology, the GCC can be separated from other retinal layers.



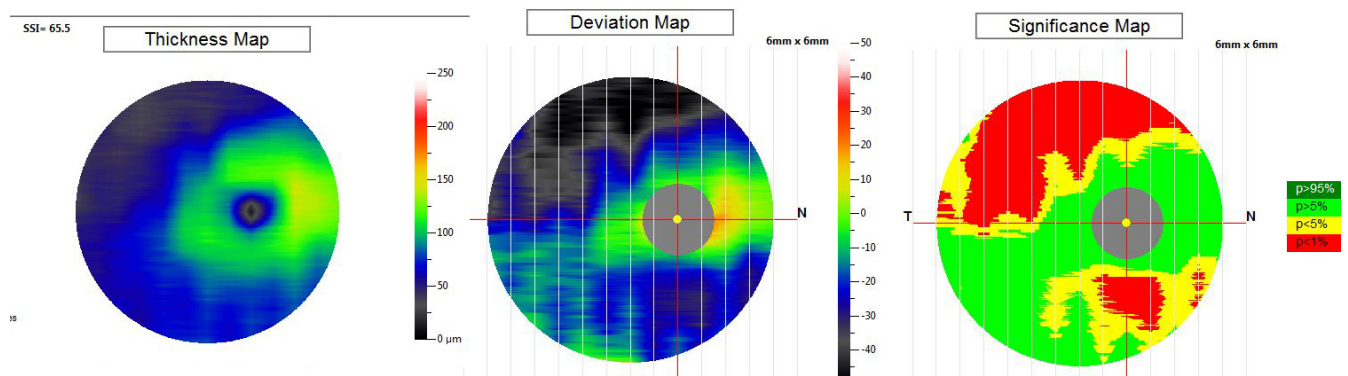
**Figure 1.** Figure 1 illustrates the segmentation of the GCC layer comprised of the NFL, GCL, and IPL compared to the segmentation of the entire retina. The high depth resolution of 5 microns helps enable this type of inner-retina segmentation that is not possible in older time domain OCT devices with worse depth resolution.

The GCC scan data is displayed as a thickness map of the GCC layer as shown in Figure 2. The thickness map is color coded where thicker regions are displayed in hot colors (yellow & orange), and thinner areas are displayed in cooler colors (blue & green). The GCC map for a normal eye shows a bright circular band surrounding the macula representing a thick GCC from healthy ganglion cells (see figure 2a). The center of the macula is thinner because there are no ganglion cells in this area. In glaucoma, as the ganglion cells are lost, the GCC complex becomes thinner (figure 2b).

**Figure 2a & 2b.** Figure 2a (left) shows the GCC thickness map for a healthy eye. Note the thick band surrounding the macula. Figure 2b (right) shows the GCC thickness map for a glaucoma patient. Note a decreased in the thickness of this band around the macula.



The GCC thickness values are analyzed and compared to an extensive normative database. This normative database is made up of over 300 healthy eyes from various ethnicities with an age range from 18-80. The value of the normative database is that it provides the clinician with the status of the patient relative to an age-matched normative database. If the patient's values are outside the normal range, the measurement is color-coded appropriately. The Deviation Map shows the *percent loss from normal* as determined by the normative database. This map is calculated by taking the actual value from a scan at each pixel location in the map, subtracting the normal value, and then dividing that by the normal value. The result is a *percent loss* value at each pixel location in the map (see figure 3). The map is color coded where blue represents GCC thinning from 20-30% relative to normal. Black coloring in the Deviation Map represent a 50% loss or greater, relative to an age-matched normal. The significance Map shows regions where the change from normal reaches statistical significance. The Significance Map is color-coded where green represents values within the normal range (p-value 5%-95%), yellow indicates a Borderline results ( p-value < 5%), and red represents an Outside Normal Limits (p-value < 1%). Figure 3 shows the Thickness Map, Deviation Map, and Significance Map for a glaucoma patient. All Deviation and Significance Maps have a circular mask in the center of the macula where the analysis is not possible due to an absence of ganglion cells in this region.



**Figure 3.** The Thickness, Deviation, and Significance Maps for a glaucoma patient. In the Deviation Map note the blue and black regions inferior and superior to the macula, corresponding to a 25% loss and 50% loss of GCC in those areas respectively. The center of the macula has a mask over the fovea because there are no ganglion cells in this area. The color scale to the right shows the percent loss associated with each color. Cooler colors such as blue and black

A parameter table is also provided for the GCC analysis. The table consists of the average GCC thickness, Superior GCC thickness, and Inferior GCC thickness. All parameters are compared to the normative database and color coded accordingly (see Figure 4).

**Figure 4.** The GCC parameter table shows the Average GCC, Superior GCC, and Inferior GCC thickness values, color-coded based on a comparison to the normative database. The table shows the results for both eyes.

Section	OD	OS
Avg. GCC (...)	93.12	93.75
Sup. GCC(μ...)	90.99	92.92
Inf. GCC(μm)	95.26	94.57

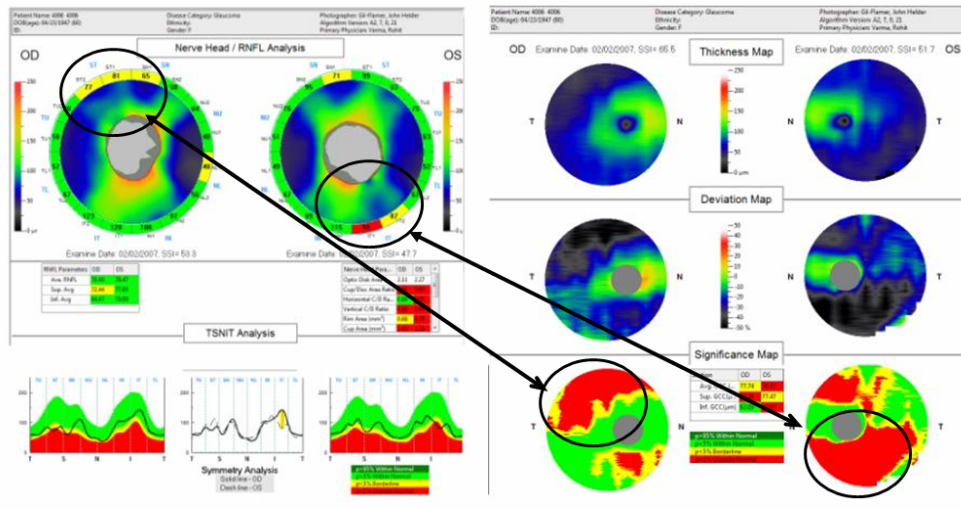
### **Comparison of GCC with Nerve Head Map**

The GCC analysis offers another important piece of structural information for a full glaucoma assessment. Imaging of the macula for glaucoma is not new. In the past, several studies have tested the diagnostic accuracy of OCT macula measurements with OCT peripapillary RNFL measurements. In 2005, Medeiros and colleagues found that the peripapillary RNFL measurements were statistically significantly more accurate for detecting glaucoma compared to the macula thickness measurements (Medeiros et al., [Am J Ophthalmol.](#) 2005 Jan;139(1):44-55). In a similar study, Wollstein and colleagues found the same results, where peripapillary RNFL measurements were significantly more accurate compared to macula measurements (Wollstein et al., [Am J Ophthalmol.](#) 2005 Jan;139(1):39-43). In both of these studies, however, the OCT used was a time domain OCT, the Stratus. The Stratus OCT has a much slower scan speed compared to the RTVue, a Fourier domain OCT system (400 A scans/ sec for the Stratus compared to 26000 A scans/ sec for the RTVue). Furthermore, the Stratus OCT has a lower depth resolution compared to the RTVue (10 micron depth resolution for Stratus vs 5 micron resolution for the RTVue). The limited depth resolution for the Stratus allowed for only full macula thickness to be measured and analyzed in both studies. The higher resolution RTVue system allows for more specific segmentation where only the retinal layers associated with the ganglion cells can be analyzed. This method of segmenting out the ganglion cell complex targets the layers directly associated with the ganglion cells, as opposed to the limited methods of the Stratus which can only analyze the entire retina thickness. In fact, a recent study reported by David Huang and colleagues from USC found that RTVue GCC values were significantly more accurate than full thickness macula values from the Stratus for detecting glaucoma in the same patients (Huang et al., AAO lecture, 2007). This study suggests that the GCC analysis may provide a more accurate assessment of glaucoma than the Stratus macula analysis. Future research is needed to compare the GCC analysis with the peripapillary RNFL analysis.

### **A case Study**

The following case study compares the Nerve Head Map scan (NHM4) from the RTVue with the GCC scan. Although this is only a single case, this patient clearly shows more extensive damage with the GCC analysis compared to the peripapillary RNFL analysis (See Figure 5).

**Figure 5.** On the left are the peripapillary RNFL results from the NHM4 scan. On the right are the GCC scan results for the same patient. Although we expect the results to be correlated, and they both show some damage present, the GCC analysis shows more extensive and severe damage compared to the RNFL analysis. Notice the large areas in the GCC Significance Map revealing extensive damage.



### Clinical Validation

Fourier Domain OCT is relatively new, and few studies have been published in peer reviewed Journals so far. There are several new reports out now about the GCC analysis with the RTVue. In one study, Takagi, Nose, Kita, and Tomita showed the GCC analysis significantly detected GCC thinning in eyes with visual field defects in one hemisphere and significantly correlated with the severity of visual field loss (**Inner Retinal Layer Measurements in Macular Region With Fourier Domain Optical Coherence Tomography in Glaucomatous Eyes With Hemifield Defects** S.T. Takagi, A. Nose, Y. Kita, G. Tomita Toho University Ohashi Medical Center, Tokyo, Japan, IOVS Suppl. 4648: 2008). In another study, Mori and colleagues found that the GCC analysis significantly differentiated normal from glaucoma and had an Area under the ROC of 0.91. The GCC analysis also significantly correlated with visual field damage (**Macular Inner and Total Retinal Volume Measurement by Spectral Domain Optical Coherence Tomography for Glaucoma Diagnosis** S. Mori, M. Hangai, H. Nakanishi, Y. Kotera, R. Inoue, S. Morishita, Y. Aikawa, F. Hirose, T. Ojima, N. Yoshimura Kyoto University, Kyoto, Japan IOVS Suppl. 4651: 2008).

These results suggest the GCC is a robust analysis that can accurately differentiate normal from glaucomatous eyes, and that the degree of GCC loss significantly correlates with the severity of visual field loss. Furthermore, anecdotal evidence suggests the GCC may detect damage before the peripapillary RNFL measurements, however this possibility requires further clinical validation and studies. These studies are currently under way.